

DENTAL GROSS ANATOMY
FIRST EXAMINATION
JANUARY 17, 2003

Name  Corrected

Questions 1 - 25 of this examination will be graded by computer and should be answered on the accompanying computer answer sheet. On the computer answer sheet your name and social security number should be PRINTED in the boxes indicated and the appropriate black marks made for the computer format of your name and social security number in the spaces below.

Write "OXBERRY" in the space provided for instructor.

Record your answer for each question on the answer sheet. Mark each correct response on the data sheet using numbers 1 through 26 with a HEAVY BLACK MARK with a #2 PENCIL. (If you erase, be sure to erase fully.)

Note that words or statements in brackets are only used to clarify or give an alternate name; they are NOT meant to change the nature of the question.

There is just ONE CORRECT ANSWER for each question.



FOR QUESTIONS 1 THROUGH 25 SELECT THE SINGLE BEST ANSWER (3 points each)

1. Starting from an upright standing position, the erector spinae on the right side of your back would undergo a lengthening contraction when you performed all the following motions EXCEPT?

C

- A. Bending to the left
- B. Bending to the contralateral side
- C. Bending to the ipsilateral side *shortening*
- D. Bending over to touch your toes



2. All of the following structures form a boundary of an intervertebral foramen EXCEPT the...

B

- A. zygapophyseal joint
- B. lamina
- C. body of vertebra
- D. intervertebral disc

3. Posterolateral herniation of the C4-C5 intervertebral disc would most likely produce pain in the...

B


- A. C3 dermatome
- B. C5 dermatome
- C. C6 dermatome
- D. None of the above



4. An injury that severs the spinal cord at the T10 vertebral level would result in a loss of function in the...

C

- A. T10 spinal nerve.
- B. T11 spinal nerve.
- C. T12 spinal nerve.
- D. All of the above



Don't get it

5. Which of the following does NOT occur when bending over to touch the floor?

D

- A. Tensile forces are placed on the posterior aspect of the intervertebral disc.
- B. The posterior longitudinal ligament becomes more taut.
- C. The anterior longitudinal ligament becomes less taut.
- D. The size of the lumbar intervertebral foramen ~~decreases~~ increases

An irritative lesion of the dorsal roots of the C5 spinal nerve could produce pain in all of the following **EXCEPT** ?

3.45

- A. skin over the shoulder pad area
- B. a zygapophyseal joint in the neck
- C. some skin over the medial 2/3 of the back of the neck
- D. diaphragm

7. Which of the following statements is **NOT** correct?

- A. The inferior extent of the conus medullaris is typically found at the L1 or L2 vertebral level.
- B. Cerebrospinal fluid is found in the subarachnoid space.
- C. The inferior extent of the dural sac is typically found at the S1 or S2 vertebral level.
- D. The internal vertebral venous plexus is found in the subdural space.

8. A destructive lesion of the left spinal accessory nerve as it crosses the posterior triangle of the neck would result in

- A. Medial winging of the left scapula
- B. Loss of the ability to abduct the left scapula
- C. Loss of the ability to shrug (elevate) the left shoulder
- D. Loss of the ability to rotate the head to right

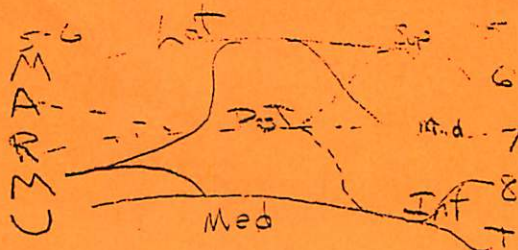
of course

9. Which of the following problems would mostly likely occur in a patient with a scalene interval syndrome?

- A. Weakness in the intrinsic hand muscles such as the interossei and lumbricals.
- B. Weakness in abduction at the glenohumeral joint.
- C. Pain or numbness in the skin over the lateral portions of the upper limb.
- D. Compression of the subclavian vein.

10. Concerning the brachial plexus,

- A. C5 and C6 ventral rami join to form the middle trunk.
- B. The anterior divisions of the superior and middle trunks form of the lateral cord.
- C. The posterior cord branches into the radial and musculocutaneous nerves.
- D. The long thoracic nerve is formed from preplexus branches of the C7, C8 and T1 ventral rami.



11. A patient is unable to abduct the upper limb to the horizontal position, is unable to flex the elbow, is unable to externally rotate the arm at the shoulder, has severe weakness in supination of the forearm and is numb over most of the lateral aspect of the upper limb, especially in the distal arm-proximal forearm region. Where is the single destructive lesion located that could produce all these deficits?

- A. ☒ Axillary nerve
 B. ☒ Posterior cord
 C. ☒ Musculocutaneous nerve
 D. ☐ Superior trunk



12. All the following muscles are internal rotators at the shoulder, EXCEPT ...

- A. ☐ Teres minor
 B. ☒ Pectoralis major
 C. ☒ Latissimus dorsi
 D. ☒ Teres major

13. The ventral rami of C3 and C4 spinal nerves contribute to ...

- A. ☐ the phrenic nerve for the motor and sensory innervation of the diaphragm.
 B. ☒ the supraclavicular nerves that innervate of the skin overlying the shoulder.
 C. ☒ the cervical plexus of nerves.
 D. ☐ all the above.

14. Which of the following muscles is innervated by dorsal rami of spinal nerves?

- A. ☐ Trapezius NOT
 B. ☒ Erector spinae
 C. ☐ Latissimus dorsi NOT
 D. ☐ Rhomboids NOT

15. Which of the following muscles is most important in order to achieve total abduction of the upper extremity (greater than 90 degrees)?

- A. ☒ Deltoid
 B. ☒ Supraspinatus
 C. ☐ Serratus anterior
 D. ☐ Levator scapulae

Initiator is supraspinatus
 from there to horizontal is deltoid
 >90° is serratus anterior

Long thoracic cut — medial wing of scapula
 spinal accessory — lateral wing

16. Which of the following nerves provides innervation ONLY to pectoralis major muscle?

- A. Lateral pectoral
B. Long thoracic
C. Medial pectoral
D. Suprascapular

17. Which of the following branches of the axillary artery would be most likely injured by a fracture of the surgical neck of the humerus?

- A. Thoracoacromial trunk
B. Lateral thoracic
C. Posterior humeral circumflex
D. Subscapular

18. In the female breast, which of the following set of lymph nodes supplies its primary drainage?

- A. Scalene
B. Parasternal
C. Axillary
D. Thoracic

Netter card
121

19. A fracture of the humerus at the level of the surgical neck could result in all of the following EXCEPT:

- A. weakness in shoulder flexion
B. weakness in shoulder adduction
C. weakness in shoulder extension
D. weakness in shoulder abduction

Axillary lateral two minor

20. Which of the following statements about the upper limb is INCORRECT?

- A. A supracondylar fracture of the humerus can result in a median nerve injury.
B. Mid-shaft fractures of the humerus frequently result in loss of elbow extension. *increased 50%*
C. The T1 dermatome includes the skin over the medial aspect of the forearm.
D. The adductor pollicis muscle is innervated by the ulnar nerve.

21. Which of the following is an INCORRECTLY matched pair?

- A. abductor pollicis longus muscle – radial nerve innervation
B. flexor digitorum profundus muscle – distal interphalangeal joint flexion
C. flexor carpi radialis muscle – wrist abduction
D. biceps brachii muscle – forearm pronation

flexor carpi ulnaris
pronator

Which of the following statements about the upper limb is INCORRECT?

- A. The interosseous muscles can simultaneously flex the MP and extend the IP joints of digits # 2 - 5.
- B. The muscle in the posterior compartment of the arm is innervated by the radial nerve.
- ☒ C. Destructive lesions of both the ulnar and the median nerves at the elbow would result in the loss of ALL thumb functions.
- D. The lateral cutaneous nerve of the forearm is the terminal part of the musculocutaneous nerve.

C56

23. During a fall on a hand with the wrist extended, the lunate bone may be anteriorly dislocated. Which of the following findings is INCONSISTENT with the motor and sensory deficits that may arise from this injury?

- A. weakness in IP flexion of digits # 2 & 3
- ☒ B. weakness in thumb opposition - *opponens pollicis*
- C. reduced sensation in the skin over the palmar surfaces of digits # 2 & 3 - *median nerve*
- D. weakness in MP flexion of digits # 2 & 3 - *lumbricals: median nerve*

flexor digitorum profundus & superficialis muscle hooking up so innervated
median nerve
ulnar nerve

24. A lesion of the C8 & T1 spinal cord segments could result in which of the following motor function deficits?

- A. weakness in elbow flexion
- B. weakness in wrist extension - *radial nerve*
- C. weakness in forearm pronation - *median nerve*
- D. weakness in finger abduction and adduction - *ulnar nerve*

median nerve
radial nerve
ulnar nerve
posterior
medial
lateral

25. Which of the following muscle - function pairings is INCORRECT?

- A. brachioradialis - elbow flexion
- B. extensor carpi radialis longus and brevis - wrist abduction
- ☒ C. extensor pollicis brevis - extends MP joint of thumb
- D. flexor digitorum superficialis - flexion of DIP joints of digits #2-5

MP & wrist flexion

flexion of PIP joints of 4 digits & contribute to MP & wrist flexion

Questions 26 - 33 of this examination are worth 3 points each and are short answer questions that require you to fill in the blank or blanks with the correct missing word or words. The answers should be written directly in the blank spaces provided on this page and the following page. Be sure to PRINT your name and official security number in the spaces provided on each of these pages. Be sure to tear off and turn in these pages at the end of the exam.

26. The superior boundary of an intervertebral foramen is formed by a pedicle.


27. A line drawn between the medial ends of the spines of the scapula would intersect the spinous process of the T3 vertebra.

C7 vertebral prominence
T3 =
T7
L4

28. The Serratus anterior muscle and the Trapezoid muscle are upward rotators of the lateral angle of the scapula, an action necessary for full abduction at the glenohumeral joint.



29. The muscles around the shoulder receive most of their innervation from terminal or preterminal nerves of the brachial plexus that contain axons from C5 and C6 ventral rami, while the muscles of the hand receive most of their innervation from terminal nerves of the brachial plexus that contain axons from C8 and T1 ventral rami.



Questions 26 - 33 of this examination are worth 2 points each and are short answer questions that require you to fill in the blank or blanks with the correct missing word or words. The answers should be written directly in the blank spaces provided on this page and the following page. Be sure to PRINT your name and social security number in the spaces provided on each of these pages. Be sure to tear off and turn in these pages at the end of the exam.

30. The suprascapular artery passes over the transverse scapular ligament to reach the supraspinous fossa.

nerve goes through the notch,
and the artery goes above the
ligament

- 3
31. In the superficial neck, the major cutaneous branches of the cervical plexus are first seen along the posterior border of the ~~platysma~~ Scm muscle.

Sternocleidomastoid

32. Name the thumb muscle that has its tendon contained within the carpal tunnel.

flexor pollicis longus

33. To test the supinator muscle in isolation, the supinator function of the biceps brachii muscle must be eliminated by placing the forearm in extension ~~flexion~~ ^{passively} extension.

END OF QUESTIONS